

CRYPTOCOCCUS

Habitat:

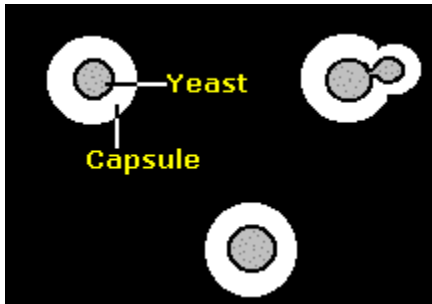
Cryptococcus is encapsulated yeast that is found in soil contaminated with pigeon droppings or eucalyptus trees and decaying wood. *Cryptococcus neoformans* grows easily in pigeon feces, however the birds are not naturally infected.

Speciation:

The genus *Cryptococcus* includes around 37 species. Among these, *Cryptococcus neoformans* is the only species that is pathogenic to humans. Other species are *Cryptococcus albidus*, *Cryptococcus laurentii*, *Cryptococcus terreus*, *Cryptococcus uniguttulatus*, *Cryptococcus luteolus* and *Cryptococcus gastricus*.

It has four serotypes (A to D). Serotyping is based on capsular agglutination reactions. It includes three varieties; var. *gattii*, var. *neoformans* and var. *grubii*. The two varieties, *neoformans* and *gattii* are morphologically similar, except that basidiospores of var. *neoformans* are round and those of var. *gattii* are more elliptical in shape. *Cryptococcus neoformans* serotype A is responsible for the majority of human cases.

Morphology:



A characteristic polysaccharide capsule of variable thickness (1-30µm) surrounds these yeasts. In its natural environment the capsule is thinner and the yeast smaller, while thicker capsules tend to be found from infected tissues. The capsules stain pink by the Meyer's mucicarmine technique.

Clinical types:

Cryptococcosis (earlier called European blastomycosis) commonly starts following inhalation of the organism. Cryptococcosis is considered an opportunistic infections as it affects mainly immunosuppressed individuals. The polysaccharide capsule, the phenoloxidase enzyme, the organism's

ability to grow at 37°C and phospholipase enzymes are its major virulence factors. It produces urease. The clinical types of cryptococcosis are pulmonary, CNS, visceral, osseous, cutaneous and mucocutaneous. The course of the infection is usually subacute or chronic. In healthy individuals, the disease is primarily pulmonary and is asymptomatic. CNS cryptococcosis such as meningitis and brain abscess are commonly seen in acute settings. Cutaneous and mucocutaneous cryptococcosis is the result of disseminated disease. In osseous cryptococcosis cranial bones and vertebrae are commonly affected. Visceral cryptococcosis follows dissemination of fungus to any organ or tissue of the body, most commonly heart, testis, prostate and eye. Patients with AIDS, carcinoma, leukemia, collagen vascular disease, Hodgkin's disease, sarcoidosis and those undergoing immunosuppressive therapy are at increased risk of cryptococcosis. The occurrence of disseminated forms of cryptococcal diseases is clearly related to immune deficiencies of the T-cells. Before the AIDS epidemic, most cases of cryptococcosis were related to cancer, especially lymphoreticular malignancies.

Laboratory diagnosis:

The specimens collected are sputum, skin biopsy, CSF etc. Globose yeast cells are seen in most clinical materials, such as CSF and pulmonary tissue mounted in 10% KOH. A capsule may or may not be present. The capsule is best visible in India ink preparations. Aspirates and tissues are inoculated onto Sabouraud dextrose agar. Colonies of *C.neoformans* are fast growing, soft, glistening, smooth, usually mucoid, and cream to yellowish brown in color. It usually takes 48 to 72 hours. It grows well at 25°C as well as 37°C. Ability to grow at 37°C is one of the features that differentiates *C.neoformans* from other *Cryptococcus spp.* *C.neoformans* produces phenoloxidase enzyme that results in production of melanin and thus a brown to black discoloration of the colony when it is grown on caffeic acid agar or bird seed agar.

Cryptococcus neoformans differs from *Candida* by hydrolysing urea and not forming pseudohyphae. Detection of cryptococcal antigens, particularly polysaccharide capsular antigen by latex-agglutination is helpful in diagnosis.